Available online at www.jpbms.info

ISSN NO- 2230 - 7885

Research article

JPBMS

JOURNAL OF PHARMACEUTICAL AND BIOMEDICAL SCIENCES

Identification of Myocardial Infarction in Human Autopsy Population Using TTC

Shenoy Revathi P, MSc, PhD [1] ,* Bakkannavar Shankar M, MD, DCL [2], Vidya Monnappa, MD, Diplomate NB[3], Bhat Akshay V,MSc [4], Mukesh Kumar, MSc,[4] Nayak Vinod C, MD [5], Pradeep Kumar G, MD, Dip.Cr.L [6].

[1]Assistant Professor, Department of Biochemistry, Kasturba Medical College, Manipal University, Manipal, India.
[2]Assistant Professor, Department of Forensic Medicine and Toxicology, Kasturba Medical College, Manipal University, Manipal, India.
[3]Associate Professor, Department of Pathology, Kasturba Medical College, Manipal University, Manipal, India.
[4]Postgraduate, Department of Biochemistry, Kasturba Medical College, Manipal University, Manipal, India.
[5] Associate Professor, Department of Forensic Medicine and Toxicology, Kasturba Medical College, Manipal University, Manipal, India.
[6] Professor & Head, Department of Forensic Medicine and Toxicology, Kasturba Medical College, Manipal University, Manipal, India

Abstract:

Myocardial infarction is the most common cause of sudden death. However the identification of myocardial infarcts at necropsy is difficult. Various methods are being used to detect it. It has been shown that the use of dyes such as nitroblue tetrazolium and 2,3,5 triphenyl tetrazolium chloride (TTC) that identify the dehydrogenase deficient infracted myocardium are largely used. But the studies have been conducted largely in animal models using these dyes. Establishing the utility of these enzyme histochemical tests at autopsy on human cadavers is the need of the hour. We studied the fourty hearts of sudden death cases staining them with TTC and thereafter confirming with histology to know the efficacy of TTC staining. Our results showed that this histochemical test is a reliable method of investigation in sudden death cases.

Key words: Myocardial infarction, 2,3,5 triphenyl tetrazolium chloride, histochemical tests.

Introduction:

Sudden unexpected deaths pose a serious problem not only to the family members but also to the treating physician if the person was admitted in the hospital for some other disease. Many a times its difficult to find out exact cause of death in such situations. Forensic pathologists along with criminal cases, deal with these sudden deaths in finding out the cause of death. According to WHO prediction, by AD 2020 up to three-quarters of death in developing countries would result from non-communicable diseases and that coronary heart disease will top the list of killers.[1] Coronary heart disease otherwise called as Myocardial Infarction (MI) is a dreaded complication of coronary atherosclerosis. The diagnosis of MI in living is attainable whereas in dead or sudden death cases, its diagnosis is difficult. Various biochemical tests have been used at autopsy to diagnose MI, by using dyes such as nitroblue tetrazolium (NBT) and 2,3,5 triphenyl tetrazolium chloride (TTC), that identify the dehydrogenase-deficient infarcted myocardium[2].

Various studies have been conducted both in animals and human hearts to know the effectiveness of the histochemical methods and also to detect the extent of myocardial infarction. Carlos et al. studied a comparison of infarct identification with Technetium 99m Purophosphate and staining with **TTC** on adult mongrel dogs [3]. Shinya M et al. demonstrated different drug combinations which reduces the myocardial infarct size on rabbits [4]. Blood perfused porcine hearts were used for the study on histochemical assessment of early myocardial infarction by Philipe NK et al.[5]. Marie JF et al. In their study found that fructose fed rats hearts are protected against ischemia-reperfusion injury [6]. Zhu X et al assessed the irreversible myocardial damage by delayed hyper enhancement Magnetic Resonance Imaging (MRI) in the hyper-acute stage in Male Sprague-Dawley rats and quantitatively compared the infarct area assessed by MRI and tetrazolium staining. They found that the irreversible myocardial damage in acute infarction, as confirmed by TTC staining, can be imaged as early as 1 hr after reperfusion with delayed hyperenhancement MRI[7].

On the other hand Adegboyega and Patrick conducted study in human autopsy population[2]. They have been shown that **TTC** staining test is sensitive, reliable and cost efficient test for the diagnosis of MI's particularly when used by pathologists who have a sound understanding of evolution of MI. In all above studies were employed TTC staining test to detect the infarct size and slices of heart were used for staining process.

The preset study conducted to assess the utility of TTC staining in the gross diagnosis of myocardial infarcts in human autopsy population using whole heart specimen instead of slices of heart.

Materials and Methods:

During medico-legal autopsy cases, the hearts were dissected out from the body and thoroughly washed under running water. After weighing, the heart was inspected for any visible abnormalities, changes and malformations and respective findings were noted. Further the heart was dissected using Inflow-Outflow technique and the findings were noted. Changes in the coronaries were documented. The dissected heart was then completely immersed in freshly prepared 1% solution of TTC, at pH 7.4 (0.1M Tris buffer) and kept in dark. The TTC solution was prepared using TTC (LOBA CHEMIE PVT LTD, Mumbai); Trizma base (Sigma Chemical Co) and HCl (to adjust the pH). The incubation was carried out in a beaker covered with petrydish. To prevent artifactual nonstaining, heart was immersed with the help of glass road so that the dissected heart does not touch a solid surface. After 20 minutes the heart was removed from the solution and observed for the staining. The non-stained area was considered as infarcted and the stained area as non-infarcted. The principle behind this staining is the presence of lactate dehydrogenase enzymatic activity in the healthy myocardial tissue. TTC is a water soluble salt, but not a dye. It is reduced by certain enzymes in normal tissue to a purple-red, fat soluble, light-sensitive compound (formazan) that turns normal tissue purple-red and thereby clearly delineates abnormal areas. Once the tissue is infarcted, the enzymatic activity is lost and the reaction with TTC will not produce colour (a purple-red) change.

To test the specificity of the TTC, the TTC stained heart was subjected for histopathological examination. Multiple sections from the various parts of the heart corresponding to the territories of all the coronary arteries and coronary arteries' sections were taken and stained with Haemotoxylin-Eosine (H & E) stain and observed under microscope for the various changes of Myocardial Infarction.

Results:

The study was conducted in the department of Forensic Medicine in collaboration with department of Biochemistry and department of Pathology, Kasturba medical college, Manipal, south India. Forty sudden death cases were considered for the study during the research period from May 2008 to April 2010. Male cases were more constituting (n=31, 77.5%) compared to female cases is depicted in ***Table no. 1***. The least age encountered in the study was 17 years in a female where as maximum age encountered was 68 years in a male.

Table No 1: **Age and gender wise distribution of cases**

Age(Years)	Males	Females
Up to 20	0	2
20 – 40	12	6
40 – 60	16	0
60 – 80	3	1
Total	31 (77.5%)	9 (22.5%)

Out of 40 autopsied hearts considered for the study, 3 were stained positive for acute Myocardial Infarction with TTC reagent as shown in ***Figure no. 1***. The positive result was inferred by suspected infarcted area remaining unstained with the TTC. These three TTC positive hearts were subjected for histopathological examination. The unstained areas showed various changes in the myocardium pertaining to infarction as showed in the ***Figure no. 2 and 3***.

Figure No 1: **Unstained area of the myocardium with TTC staining**

Figure No 2: **Acute myocardial infarction (Heamotoxylin and Eosin, 40X). Section shows Contraction band necrosis of the myocardium.**

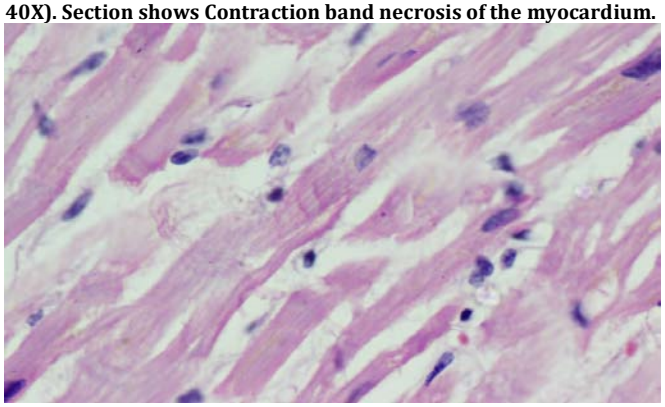

Figure No 3: **Acute myocardial infarction (Heamotoxylin and Eosin, 20X). Section shows Necrotic myocardium with neutrophilic infiltration.**

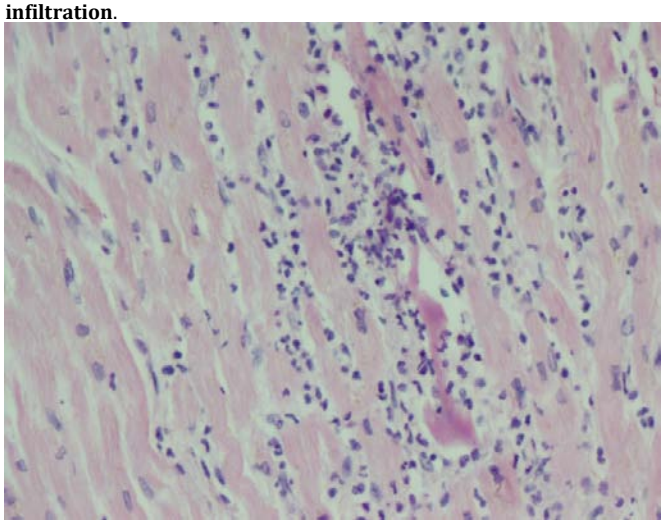

Histological examination did not reveal acute infarcts in any of the remaining 37 cases that did not remain unstained with TTC. The no. of TTC positive and histopathology positive cases were shown in ***Table no. 3***. The use of TTC in macroscopic diagnosis of acute MI has 100% specificity and 100% sensitivity.

The duration between the incidence and TTC staining at autopsy was ranging from 30 minutes to 3 days as depicted in ***Table no. 2***. The duration in three TTC positive

and histology positive cases was10.30hrs, 13hrs and 18hrs which showed contraction band necrosis and necrotic myocardium at histology as shown in ***Figure no. 2 and 3.***

Table No 2: **TTC and histopathology confirmed cases**

	TTC	Histopathology	Both
Positive	3	3	3
Negative	37	37	37

Discussion:

The present study brightens the light in the field of macroscopic diagnosis of myocardial infarction by a forensic pathologist. It provides the evidence of the use of TTC as a useful and reliable method for detecting well-established MI as well as early irreversible injury of myocardium at autopsy. Diagnosing an infarct in cases of sudden death or confirming a clinical diagnosis of myocardial infarction by demonstrating histologically is an imperative component of the autopsy. Diagnosis at autopsy of patients with myocardial infarction occurring within hours of death is often difficult when the time lag between an irreversible ischemic insult to the myocardium is insufficient for the development of gross and histologic changes indicative of necrosis, which occur no sooner than 6-12 hours after the onset of severe ischemia [8, 9].

Biochemical alterations occurring in any tissues following injury form the basis of pathological changes observed subsequently. Various studies have been conducted by workers to recognise these biochemical alterations. In heart, following myocardial injury or death, various electrolytes like K^+, Mg^{++}, PO_4 etc and various enzymes and low molecular weight co-factors diffuse out of dead cell into interstitial space and enter the blood stream[10]. Estimation of increased quantities of myocardium specific enzymes indicates the myocardial injury or death. At the same time, the decreased activity of these enzymes can be demonstrated by histochemical changes. Even though various enzymes have been studied in this context, maleic dehydrogenase (MDH), lactic dehydrogenase (LDH) and succinic dehydrogenase (SDH) are useful in autopsy materials [11]. The SDH though less sensitive resists post mortem autolysis better. The Triphenyl tetrazolium Chloride (TTC) reaction depends upon the activity of these enzymes. The inactivation of dehydrogenase enzyme due to leakage out of the cell or exhaustion of glycogen stores from within the dead cell, leads to non deposition of formazan pigments over the area of infarction.

Inactivation of these enzymes is time bound but variable. It can be noticed as early as five hours [11]. The technique of demonstration of this enzyme inactivity is not affected by post-mortem changes up to first 36 hours and if refrigerated, up to 60 hours [12]. Wachstein and Meisel found the inactivation of SDH as early as two hours after the onset of acute symptoms [13]. Kotabagi et. a.l noticed this change in hearts more than 5 ½ hours of post infarction[10]. Fishbein et al, in their study found out that using TTC, necrosis can be quantitated reliably 6, and even 3 hours after coronary occlusion, before histologic changes are clearly diagnostic and the technique represents a reliable, practical means for quantitation of recent infarction and for studying the evolution of ischemic injury in its early phase [14].

Thus our study confirms the usefulness of TTC staining in detecting infarcts in suspected cases at autopsy. Even this proves that the refrigerated bodies will have an advantage over the non refrigerated bodies and petrified bodies which is an established factor.

Conclusion:

Diagnosis of myocardial infarction at autopsy is not only a challenging task for the forensic pathologist but also a essential step from the point of ascertaining the cause of death in sudden deaths. We conclude considering the factors observed in the study, that the TTC staining is an important tool at autopsy in cases of sudden deaths. It is more useful in cases up to 36 hours of post-mortem interval. We recommend the staining technique to be included in the autopsy of sudden deaths. As our study comprises less samples, more and more studies need to be conducted to establish the definitive data regarding the utility of TTC.

Funding:

Research grant, Kasturba Medical College, Manipal University, Manipal.

Acknowledgement:

This work was supported by Kasturba Medical College, Manipal University Research Grant.

The authors wish to acknowledge Prof. Sudhakar Nayak, Head of the Department of Biochemistry and Prof. Laxmi Rao, Head of the Department of Pathology, KMC, Manipal University, Manipal, India for supporting this work in their departments. We also like to thank staff members of Forensic Medicine, Pathology and Biochemistry and mortuary technicians for their constant support during the study.

References:

1.Yeolekar ME. Coronary artery disease in Asian Indians. J Postgrad med 1998; 44: 26-28.

2.Adegboyega, Patrick A, Adesokan, Adekunle, Haque, Abida K, Boor, Paul J. Sensitivity and specificity of triphenyl tetrazolium chloride in the gross diagnosis of acute myocardial infarcts. Arch of Pathol Lab Med. 1997; 121: 1063 – 68.

3.Carlos Lzquierdo, Michael D.Devous, Sr.,Pascal Nicod, L. Maximillian Buja, Robert W.Parkey, Fredrick J.Bonte,James T.Willerson, and Samuel E. Lewis. Comparison of infarct identification with technetium-99 pyrophosphate and staining with triphenyl tetrazolium chloride. J Nucl Med. 1983; 24: 492 – 97.

4.Shinya Minatoguchi, Ningyuan wang, Yoshihiro Uno, Masazumi Arai, Kazuaki Hashimoto, Yasuko Hashimoto, Xue-Hai Chen , Genzou Takemura and Hisayoshi Fujiwara . Combination of miglitol, an anti-diabetic drug and nicorandil markedly reduces myocardial infarct size through opening the mitochondrial K_{ATP} channels in rabbits. British Journal of Phamacology. 2001; 133:1041 – 46.

5.Philipe N. Khalil, Matthias Siebeck, Ralf Huss, Matthias Pollhammer, Maurice N. Khalil, Christiane Neuhof and Hans Fritz . Histochemical assessment of early myocardial infarction using 2,3,5-triphenyltetrazolium chloride in blood-perfused porcine hearts. Journal of Pharmacological and Toxicological Methods. 2006; 54(3): 307 – 12.

6.Marie Joyeux-Faure, Eliane Rossini, Christophe Ribuot, and Patrice Faure. Fructose –Fed rat hearts are protected against Ischemia- reperfusion injury. Experimental Biology and Medicine. 2006; 231: 456 – 62.
7.Zhu X, Zhang1 R, Campagna1 N. F, M. Zhao. Assessment of Irreversible Myocardial Damage by Delayed Hyper enhancement MRI in the Hyper-Acute Stage. Proc Intl Soc Mag Reson Med. 2005; 13: 232.
8.Mallory GK, White PD, Salcedo-Salgar J: The speed of healing of myocardial infarction: A study of the pathologic anatomy in 72 cases. Am Heart J. 1939; 18: 647 – 671.
9.Fishbein MC, Maclean D, Maroko RP: The histopathologic evolution of myocardial infarction. Chest. 1978; 73: 843 – 49.
10.Kotabagi RB, Apte VV, Pathak PR. Postmortem diagnosis of early myocardial infarction. Med J Arm ForInd. 2000; 56: 99 – 102.
11.Guharaj PV's Forensic Medicine, Edited by Chandran MR, 2nd Edn; Orient Longman Private Limited, Chenni. 2006: 76 – 78.
12.Knight B. In: Camps FE, Editor, Myocardial Ischemia-Recent advances in Forensic pathology. 1969: 20-34.
13.Wachstein M, Meisel E. Succinic dehydrogenation activity in myocardial infarction and induced myocardial necrosis. Am J Path. 1995; 33: 353.
14.Fishbein MC, Meerbaum S, Rit J, Lando U, Kanmatsuse K, Mercier JC, Corday E, Ganz W. Early phase acute myocardial infarct size quantification: validation of the triphenyl tetrazolium chloride tissue enzyme staining technique. Am Heart J. 1981; 101(5): 593 – 600.

Corresponding Author:-
Dr Shankar M Bakkannavar.,
Assistant Professor,
Department of Forensic Medicine & Toxicology,
Kasturba Medical College, Manipal-576104, India.
Conatct No. +91-820-2922450 (O)
+91-9845303881 (M)
Email Id:-shankar.mb@manipal.edu

Source of funding: - Research grant, Kasturba Medical College, Manipal University, Manipal, India.